

Can Ultrasound Be an Effective Imaging Tool in Life Threatening Complications of Pregnancy?

Gihan Hassan Gamal^{1,*}, Lamyaa M. Yosry²

¹ Department of Radiodiagnosis, Faculties of Medicine, 6th October University

² Obstetrics and Gynecology, Faculties of Medicine, Al-Azhar University

ABSTRACT

Acute life threatening complications can arise during pregnancy and early postpartum period and result in maternal and fetal morbidity and mortality. Common clinical signs are vaginal bleeding and pelvic or abdominal pain. The aim of this work was to improve the role of Ultrasound in identifying the causes, differential diagnosis and management of major acute life threatening complications of pregnancy. Sixty eight pregnant women complaining of vaginal bleeding with pelvic or abdominal pain were followed up in the US out patients, US emergency unit at 6th October hospital over a period of one year. Ten cases were in the postpartum period and the remaining cases were at different ages of gestation. They were examined by trans abdominal, using 3.5 MHz sector probe or transvaginal technique according to the suspected clinical examination. Our results could depict, according to US findings, five groups of pregnant complications: ectopic pregnancy, placenta previa, placenta morbid adhesion, placenta abruption and retained product of conception. **Conclusion** It was proved that US is an important and helpful tool in investigation and diagnosis of threatening life complications of pregnancy, but should not override the clinical obstetric judgment.

Key Words

US : Ultrasound, MHz : Megahertz.

Correspondence to:

Gihan Hassan Gamal

Department of Radiodiagnosis,

Faculties of Medicine,

6th October University, 6th October City,

6th of October Governorate, Egypt.

E-mail: dr.gh_006@yahoo.com

1 Introduction

Vaginal bleeding associated pelvic or abdominal pains are the most common complains of pregnant women presenting to the emergency department. In addition to clinical history, physical examination and laboratory data, ultrasound imaging is very essential for evaluating these patients. Ultrasound technique in the last few decades has provided ultrasound machines of high quality and resolution with the option of compact and mobile unit. Grey scale and Doppler facilities have made ultrasound a useful tool for obstetrical assessment and diagnosis of life threatening complications in pregnancy. Ectopic pregnancy, morbid adhesion of placenta, placental abruption, placenta previa and retained product of conception are some of the most common emergency conditions during pregnancy and the immediate postpartum period (Kadasine A.R and Merghani H.M, 2011).

Shaw et al. (2010) stated that ultrasound examination is an important and helpful tool in investigation and diagnosis of threatening complications of pregnancy, but should not override the clinical obstetric judgment.

Tikkanen M. (2011) stated that, the presenting complains in these cases are usually vaginal bleeding with pelvic and abdominal pain and he added that ultrasound proved to be an important tool in diagnosis and management of emergency conditions of pregnancy and early post partum period.

2 Subjects and Methods

Sixty eight pregnant women presenting with clinical pictures of threatening life complications of pregnancy (severe vaginal bleeding, pelvic and abdominal pain and shock) were collecting over period of one year. Their diagnosis and differential diagnosis were of essential need for rapid management and saving life of both mother and fetus. They were examined by high resolution US machine using 3.5 MHz sector probe for transabdominal scanning or transvaginal probe for endovaginal scan, according to the suspected diagnosis. The study was carried at outpatient US emergency Unit of 6 October University Hospital. Our work could depict 5 groups of life threatening pregnant emergencies.

- Placenta previa was detected in 10 cases.
- Morbid adhesion of the placenta was detected in 2 cases.
- Placenta abruption was detected in 3 cases.
- Retained products of conception were in 50 cases.
- Ectopic pregnancy was detected in 3 cases.

Technique of placental scanning:

As a general rule, the highest frequency transducer which provides adequate penetration was used. In transabdominal imaging, we used 3.5 - 5MHz. It was essential for ensuring optimum image quality. We applied

coupling Gel to the patients skin to ensure an air free contact between the patient and the transducer face. Types of transducers used were sector, curvilinear or straight linear probe according to the case examined. Most scans were performed with the woman supine. Trendelenberg position scanning was needed to detect the inferior placental margin. Optimal bladder distention was requested in those of less than 1 week gestation or in women whom a low lying placenta was suspected. Scanning started from the umbilicus to the symphysis pubis longitudinally in the midline and then more laterally on both sides. Transverse scanning was done only over the lower pelvis.

Transvaginal scanning was done for proper visualization of the placenta using 5 MHz edovaginal probe with the patients in a supine lithotomy position. Bladder should be empty, the probe should be disinfected before use and be covered by a latex condom and lubricated by GK Gell.

The umbilical artery was sampled at the middle of the umbilical cord. This was achieved by placing the probe in the middle of the abdomen just below the umbilicus. Change the gain setting was done till the wave form fills about two thirds of the screen. Doppler scanning of the umbilical vein was also assessted.

Utero- Placental vascular wave forms was also assessted through transabdominal imaging.

3 Results

Sonographic and color duplex findings for the sixty eight women included in this study revealed five groups of life threatening pregnant emergencies. Each of them showed characteristic ultrasound findings. Placenta previa were diagnosed by US in 10 cases. Transabdominal ultrasonography done allowed adequate visualization of the area of the internal os. Longitudinal and transverse scans were performed to determine the relation between the lower borders of the placenta to the internal os. Transabdominal US with half filled

urinary bladder could properly depict the low position of placenta. Endovaginal ultrasonography was more accurate in detecting and specified the types of placenta previa. It was in five cases 2cm or less, in three cases the placenta was covering completely the internal os. In the remaining two cases, the placenta incompletely covered the internal os. The first group was known as low-lying placenta, the second group as complete placenta previa or central complete placenta previa, and the third group was eccentric placenta..

Morbid adhesion of the placenta was detected in two cases. In this condition, there was an abnormal penetration of the chorionic villi into uterine wall. US showed thinning of the retroplacental hypochoic zone, presence of multiple placental lacunae and elevation of tissue beyond the uterine outer layer. Doppler sonography revealed turbulent blood flow at the uteroplacental interface. Both cases gave history of multiple CS Delivery.

Placenta abruption: Only three cases were seen along the period of the study denoting premature separation of the placenta implanted in the upper segment of the uterus. External trauma was the preexisting factor in those cases. US showed sonolucent areas between the placenta and uterus and thickened placenta.

Retained Product of conception was detected in 50 cases. All of them were presented by severe vaginal bleeding. Ten cases had, in addition, signs of infection. Two cases were in shock.

The products were resulting from spontaneous pregnant loss in 35 cases

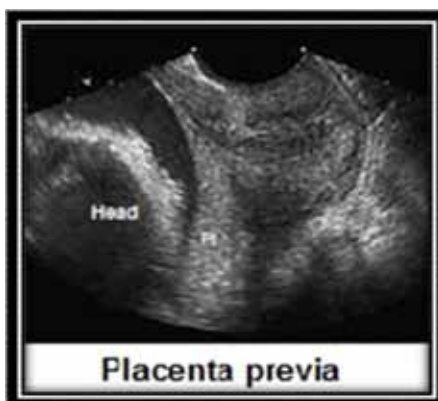

Fig.1. Placenta previa.

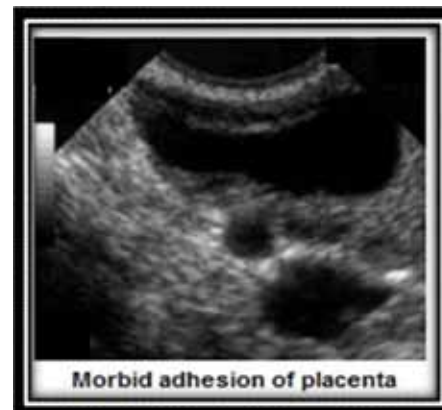

Fig.2. Morbid adhesion of placenta.

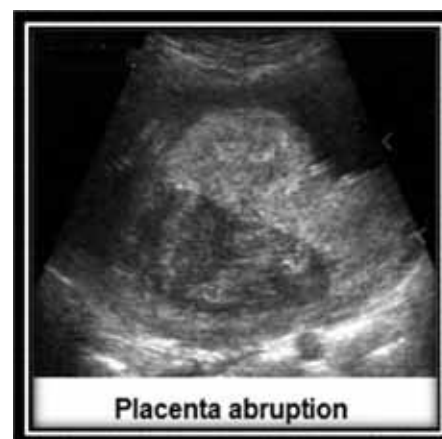

Fig.3. Placenta abruption.

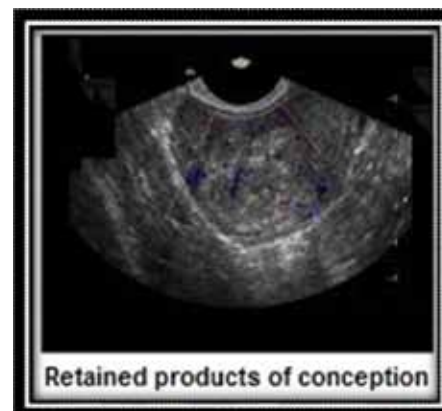


Fig.4. Retained products of conception.

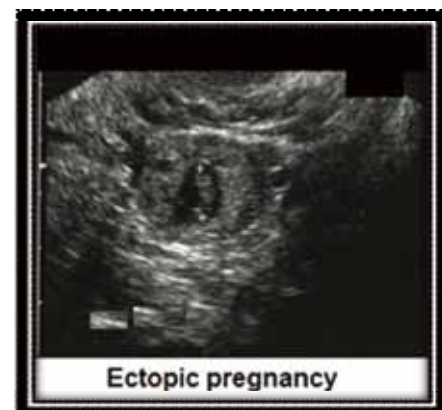

Fig.5. Ectopic pregnancy.

and planning pregnant termination in 5 cases suffering from other medical disorders. The remaining ten cases were in preterm and term delivery state US findings revealed heterogenous hyper echogenic material filler the utrine cavity with thickening of the endometrium.

4 Discussion

Marrian G. et al., (2011) stated that placenta previa is a condition, in which the placental tissue implanted, abnormally in the lower uterus. It is of two types: low lying placenta or marginal placenta previa and major placenta previa or central type. Cesarean section and uterus curettage are most of the predisposing factors. The possibility of one of these diagnosis complicating placenta previa must be excluded.

Yeo and Ananth (2008) stated that the neonatal mortality and massive postpartum hemorrhage and maternal near miss cases are of high possibility with placenta previa. The sensitivity of ultrasound examination in detecting placenta previa is more than 95%. Transvaginal or perineal evaluation is adequate with 1% false +ve and 2% false -ve rate. Digital vaginal examination is contraindicated.

Masselli G. et al. (2008) stated that transabdominal US with mildly filled urinary bladder is the best approach to confirm placenta previa implanted in the anterior wall.

Marrian G. et al. (2011) stated that any of the following US criteria exclude placenta previa:

Direct apposition of the presenting part of the fetus and cervix without space for interposed tissue, the present of amniotic fluid between the presenting part of the fetus and the cervix. And a placental distance of greater than 2cm between the inferior aspect of the placenta and the internal os. He also recorded that sonography is more than 95% accurate in diagnosis of placenta previa while transvaginal evaluation of placenta previa has 1% false +ve and 2% false -ve rate and concluded that transabdominal US is the best test of

choice to confirm placenta previa. He also stated that, care should be taken not to mistake a more serious situation such as placenta abruption or placenta accreta for placenta previa, because the management of these conditions is different. The possibility of one of these diagnoses, complicating placenta previa must be excluded.

Our findings are exactly agree with the previous results and we add that the transabdominal US was quite enough to detect placenta previa with high accuracy using 3.5 MHz probe.

Yeo and Ananth (2008) stated that morbid adhesion of the placenta occurs when placenta attached to the superficial layer of myometrium instead of endometrium. He further categorized it into two subtypes, placenta increta when the chorionic villi penetrate the myometrium and placenta percreta when the placenta penetrates the whole utrine wall reaching peritoneal layer. In pregnancy complicated by morbid attached placenta, the placenta does not easily separated from the utrine wall during the 3rd stage of delivery causing severe postpartum hemorrhage which needs blood transfusion. Arterial embolization or an emergency hysterectomy may be highly required.

Cristine H. et al., (2003) stated that the main ultrasound features are thinning of the retroplacental hypoechoic zone with the presence of multiple placental lakes. Sebire. and Sepulveda in 2008 stated that the incidence of placenta accrete increases due to repeated C.S. delivery. Women with placenta previa have a substantially increase risk of placenta accreta. MRI and US are best imaging modalities used to confirm the diagnosis.

Kadasine and Merghani (2011) Stated that ultrasound findings of morbid adhesion of the placenta are thinning of the retroplacental hypoechoic zone, present of multiple placental lakes, thinning of the uterine serosa-bladder wall complex, elevation of the tissue beyond the uterine serosa, turbulent or complicated blood flow at placental interface and irregular blood flow

underlying the maternal urinary bladder.

Alsereh et al. (2007) stated that transvaginal and transabdominal ultrasonography are complementary diagnostic technique and should be used as needed. Abnormal placental attachment site is characterized by a hypoechoic boundary between placenta and the bladder. The ultrasound findings suggest of placental morbid adhesion include irregularly shaped placenta lacunae (vascular spaces) within the placenta, thinning of myometrium overlying the placenta, loss of retroplacental clear space, protrusion of the placenta to the urinary bladder, increased vascularity of the utero-serosa interface and turbid blood flow through the lacunae on Doppler ultrasound.

GREY SCALE ultrasound is sufficient to diagnose placenta with sensitivity of 77% -89% and specificity of 96% -98%. The use of Doppler US or 3D imaging does not significantly improve the diagnostic sensitivity compared with that achieved by grey scale US alone.

ULTRASOUND findings include obliteration of normal anechoic space behind the placenta, and abnormal placental vascularity by color Doppler show hypervascularity of dilated lacunar spaces.

We only depict in our result two cases of morbid adhesion of placenta. The main US findings were thinning of retroplacental hypoechoic zone with multiple placental lacunae. In both cases turbid blood flow was detected by Doppler US at utero placental interface.

Cristine H. et al., (2003) stated that antenatal US is the technique of choice to establish the diagnosis and guide to clinical management. Signs of accretion may be seen as early as in the first trimester. All had low lying gestation sacs which are clearly attached to the uterine scar. The myometrium was thin in the area of the scar to which the sac is attached.

Placenta abruption is a condition in which the placenta, implanted in the upper segment, peels from the utrine wall, partially or almost completely before birth, in mild cases cause few problem,

and in severe cases can deprive the baby of oxygen and nutrients. It also causes bleeding which may be dangerous to both mother and the fetus. It causes 10% of premature birth of fetus of high risk of health problems (Eller et al. 2009).

External trauma, eclampsia, hypertension, vascular diseases are among the most common risk factors. Ultrasound findings in these cases may be one or more of these findings: preplacental collection (under chorionic plate), jell-like movement of chorionic plate with fetal movement, retroplacental collection (between placenta and myometrium), marginal collection (at placental margin), increase placental thickness or echogenicity more than 4-5 cm throughout pregnancy and intra amniotic hematoma (Yeo and Ananth, 2008).

On the other hand Tikkanen in 2011 stated that the sensitivity of an ultrasound examination in detecting placenta abruption is as low as 25%, therefore physicians should rely on the clinical presentation for diagnosis as vaginal bleeding, abdominal pain, tachycardia, drop in blood pressure hard abdomen and signs of fetal distress and so requesting US examination in such patients is of little significance and might waste valuable time.

Eller et al. (2009) stated that the size and location of abruption identified by US may be important prognostically. Retroplacental collections have a worse prognosis for fetal survival than subchorionic collection. In addition a large retroplacental hemorrhage has been associated with 50% fetal mortality.

Yeo and Ananth (2008) stated that the US features of placenta abruption are preplacental collection under the chorionic plate, jell-like movement of chorionic plate with fetal movement, retroplacental collection, collection at placental margin and lastly placental thickness or echogenicity more than 5cm perpendicular to the plane of placenta throughout pregnancy. Eller et al. (2009) described placenta abruption as partially or completely peeling of the placenta from the uterine wall before birth, severe

cases can deprive the baby of O₂ and nutrients and it also causes bleeding which may be dangerous to both mother and fetus, it can appear as an ill defined echogenic collection either hyperechoic or isoechoic with respect to the placenta seen.

Our results of the 3 cases of placental abruption were presenting at immediate post partum period by severe vaginal hemorrhage, US findings revealed retroplacental collection with thickened placenta. We agree with the opinion of Soisson in that the size and location of abruption identified by US has very important prognostic markers where our two cases showed worse prognosis for fetal survive.

Retained Product of Conception refers to placenta and / or fetal tissues that remains in the uterus after spontaneous pregnant loss (miscarage), planned pregnant termination, or preterm / term delivery. Women presenting with vaginal bleeding and / or signs of infection. Transvaginal sonography and clinical data are complementary for more accurate diagnosis. Karimpour M. et al. (2010).

Shaw J.I et al, (2012) Stated that between several diagnostic findings, only endometrial thickening significantly correlate with the presence of retained product of conception where endometrial thickness greater than 12mm has the best value for confirming presence of retained product of conception.

Tikkanen (2011) stated that ectopic pregnancy is still remains to be a common cause of maternal morbidity and mortality, the major causes of death are excessive hemorrhage, shock, and renal failure, therefore ectopic pregnancy must be excluded in every women in childbearing age. Ultrasound finding shows a normal intrauterine gestation sac is eccentrically placed in the endometrial cavity and surrounding by a double decidual layer, the presence of the yolk sac confirm the diagnosis.

Ectopic pregnancies are classified into tubal pregnant (fallopian tube), non tubal (in adenxia or ovary), heterotopic two fertilized eggs, one outside uterus

and other inside uterus) and persisted ectopic continuation of trophoblastic growth after a surgical intervention to remove an ectopic pregnancy, as concluded by Yeo and Ananth (2008).

Conclusion: It was proved that US was an important and helpful tool in investigation and diagnosis of threatening life complications of pregnancy, but should not override the clinical obstetric judgment.

References

1. Alsereh A, Moyan A, Brown F. Placenta accreta, an association with fibroid. *J Ultrasound Med* (2007) 10: 1159-1165.
2. Cristine H, Comstock E, Richard A, Bronsteen S. Early sonographic appearance of placenta accreta. *Brit J Obstet Gynecol* (2003)105: 235-240.
3. Eller AG, Piorter TF, Soisson P, Silver RM, et al. Optimal management strategies for placenta problems. *Brit J Obstet Gynecol* (2009) 107: 1166-1170.
4. Kadasine AR, Merghani HM. Role of ultrasound in life threatening situation in pregnancy. *J Emergencies Trauma Shock* (2011) 701: 1213-1220.
5. Karimpour M, Daniela A, Carusi C. Accuracy of transvaginal sonography in detecting retained products of conception in correlation with pathological and clinical findings. *AJR* (2010) 175: 767-773.
6. Marrian G, Chief F, Eugene C. Life threatening complications of pregnancy, key issues in diagnosis and management. *Eur Radiol J* (2011) 55: 611-618.
7. Masselli G, Brunelli R, Cascian RM. MRI in correlation with ultrasound in evaluation of placental disorders. *Eur J Radiol* (2008) 79: 905-910.
8. Shaw JI, Dey SK, Home AW. Knowledge of the etiology of human tubular ectopic pregnancy. *Acta Obstet Gynecol* (2010): 573-575.
9. Sebire NJ, Sepulveda W. Correlation of placenta pathology with prenatal ultrasound findings. *J Clin Pathol* (2008): 266-267.
10. Tikkanen M. Placenta abruption: Epidemiology, risk factors and consequences. *Acta Obstet. Gynecol Scand* (2011) 77: 334-340.
11. Yeo I, Ananth C. Placenta abruption, presents a major health problem for women of child bearing age. *Ultrasound Eur J* (2008) 215: 428-431.